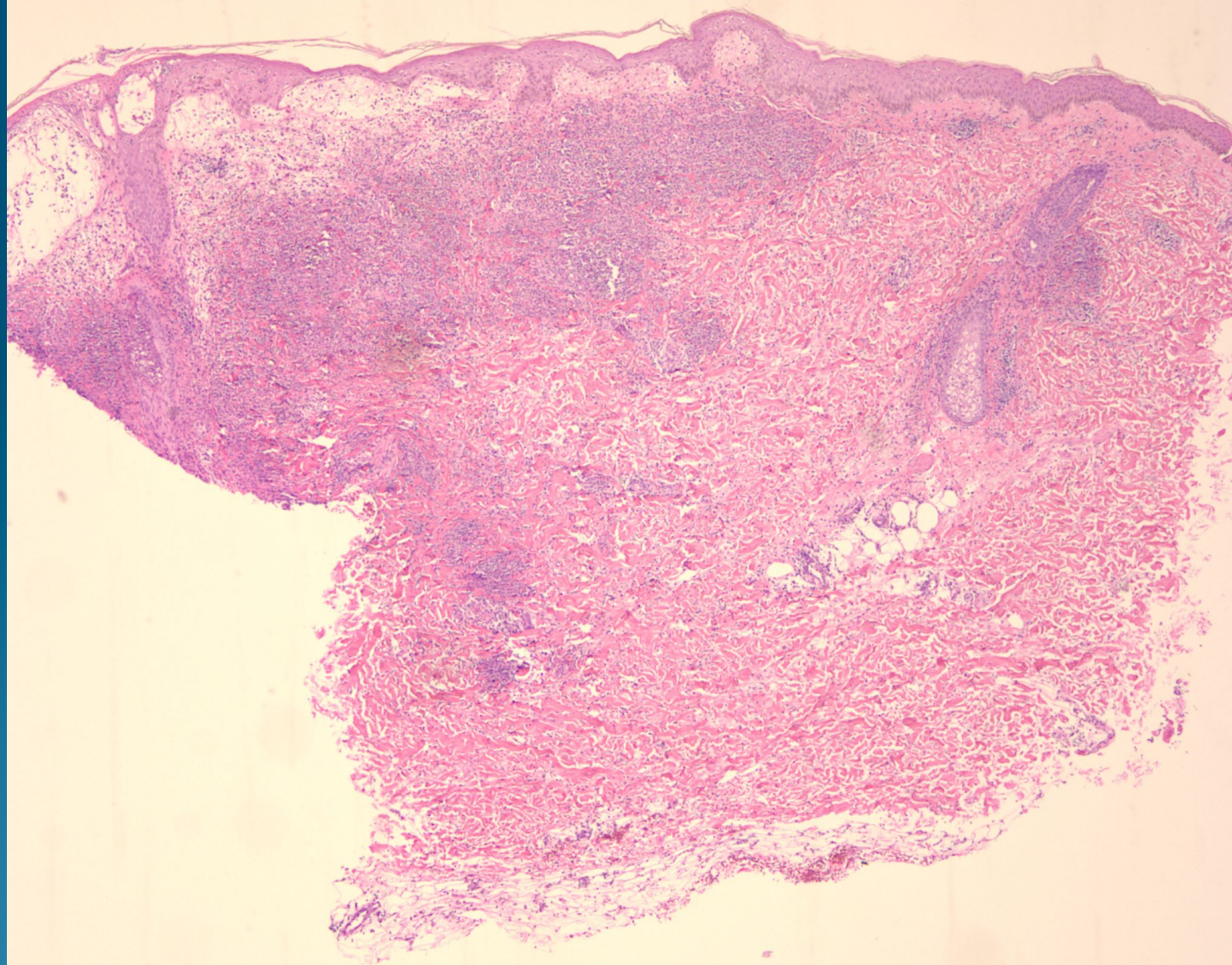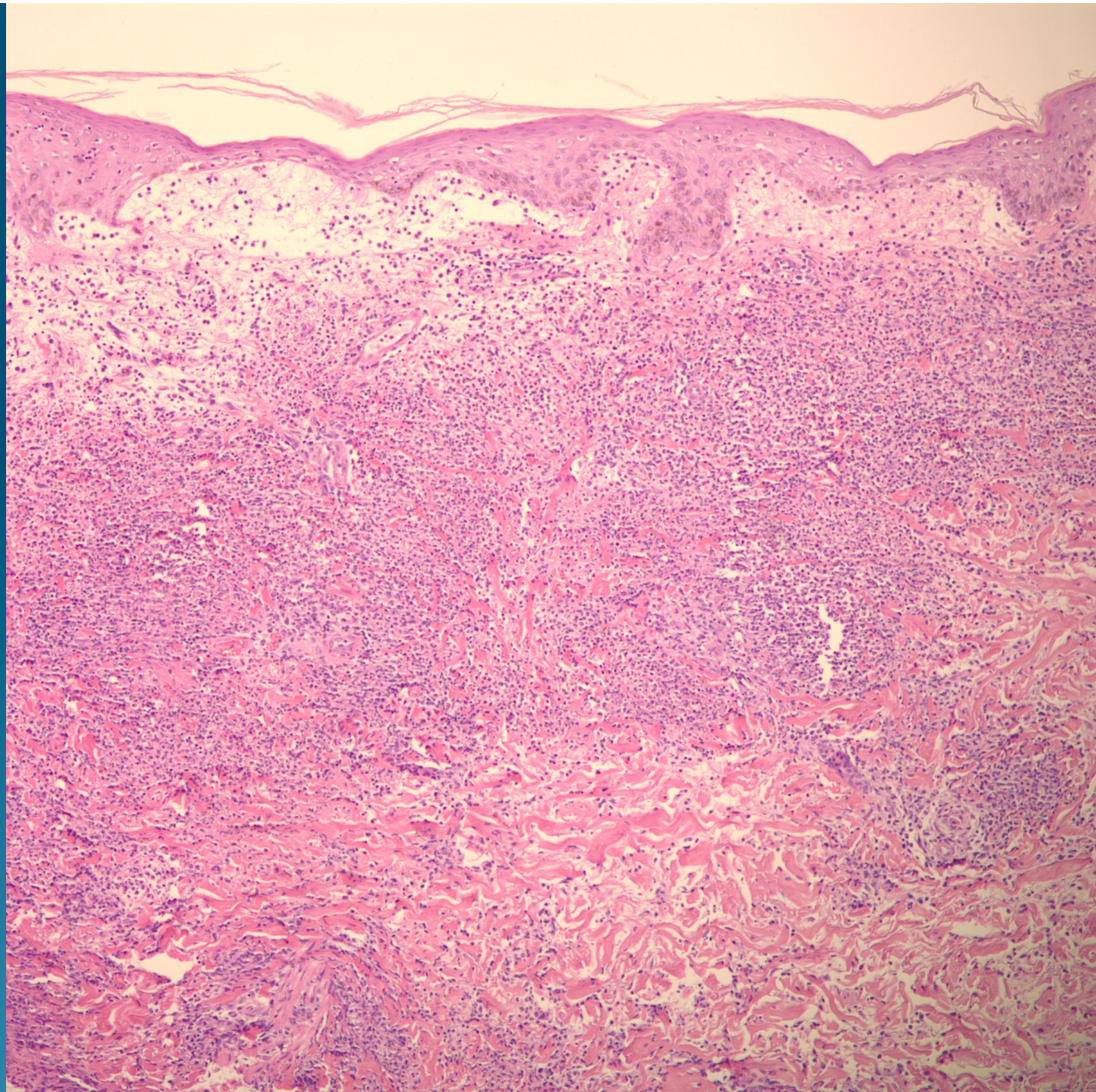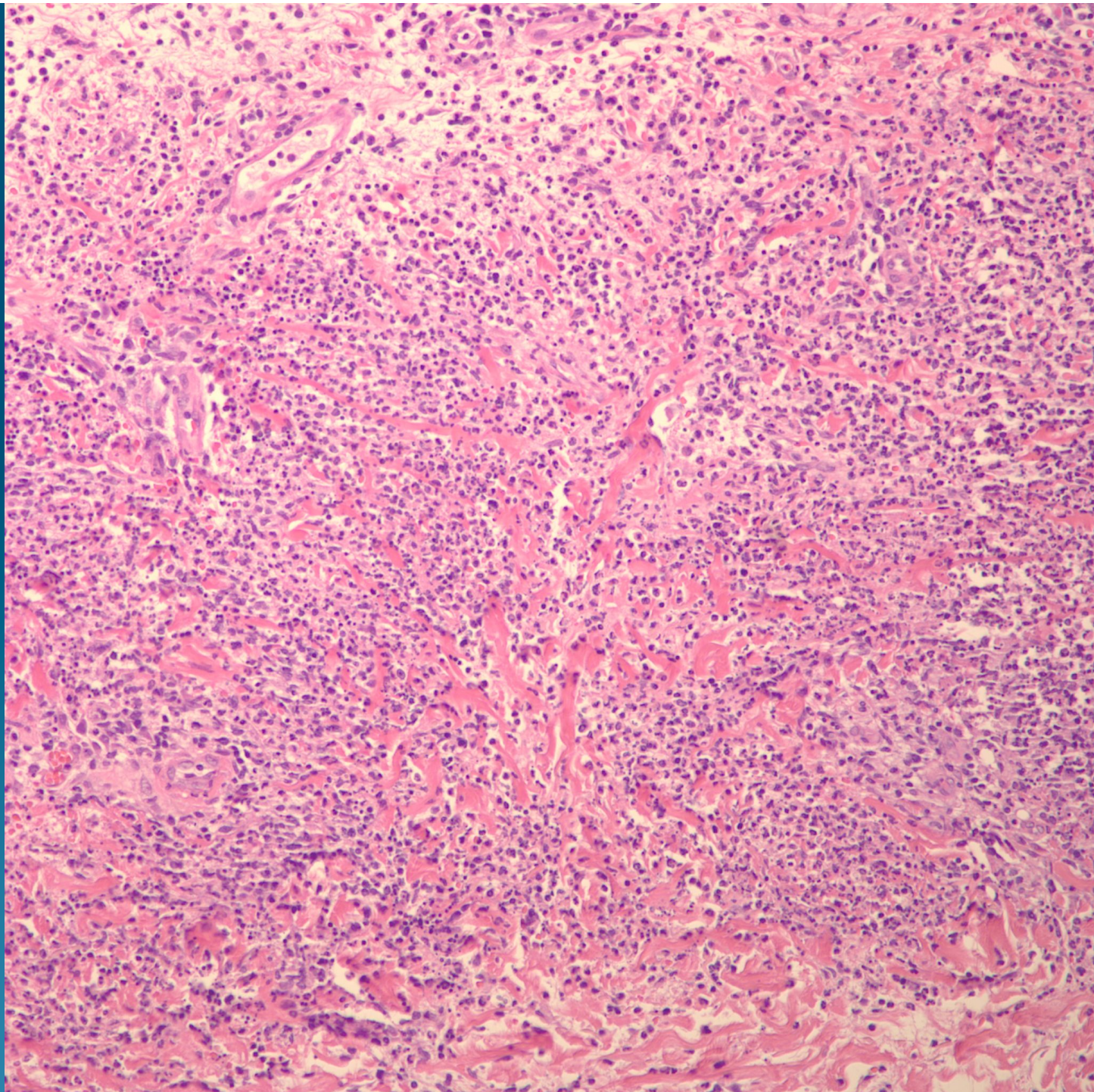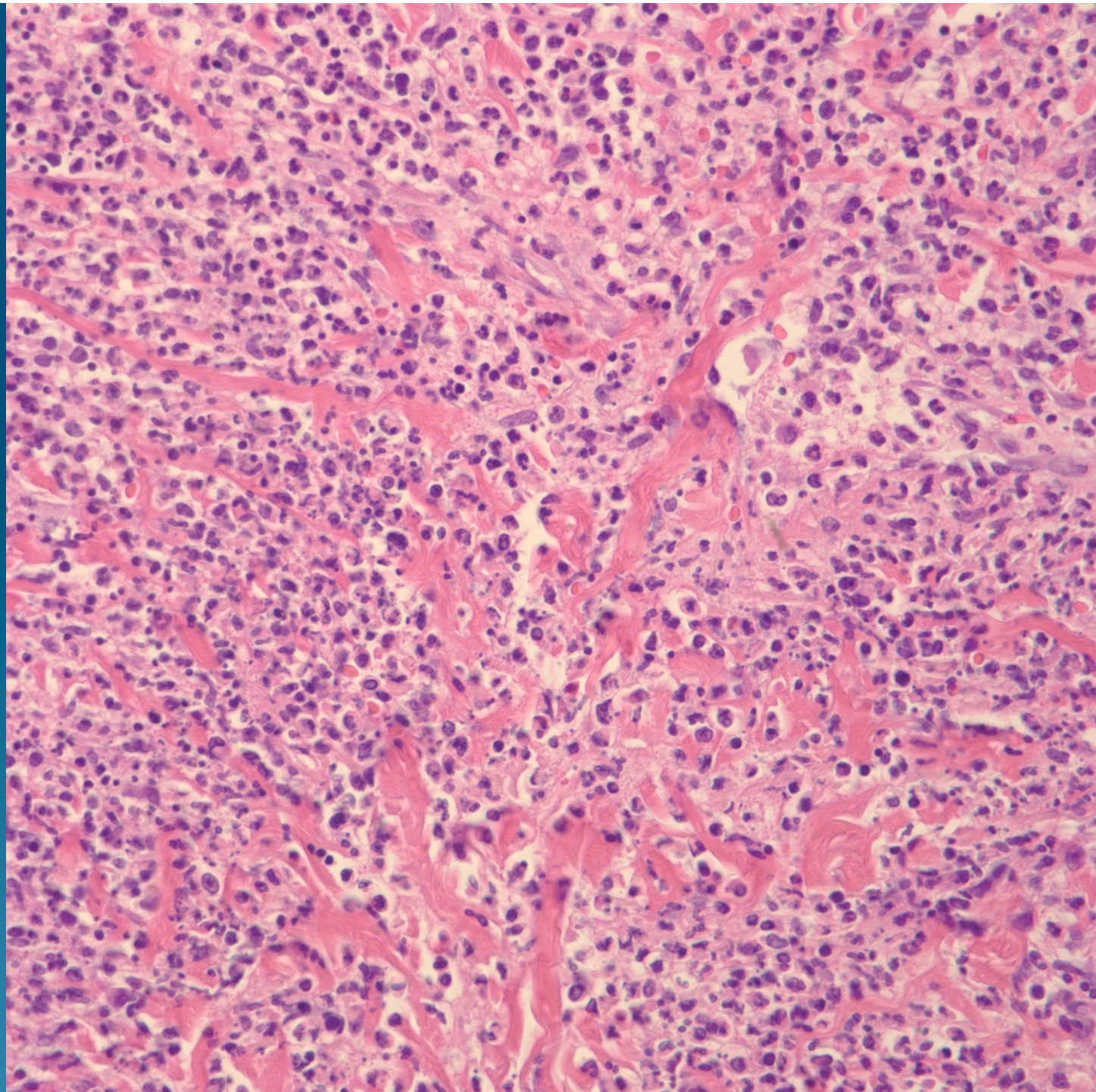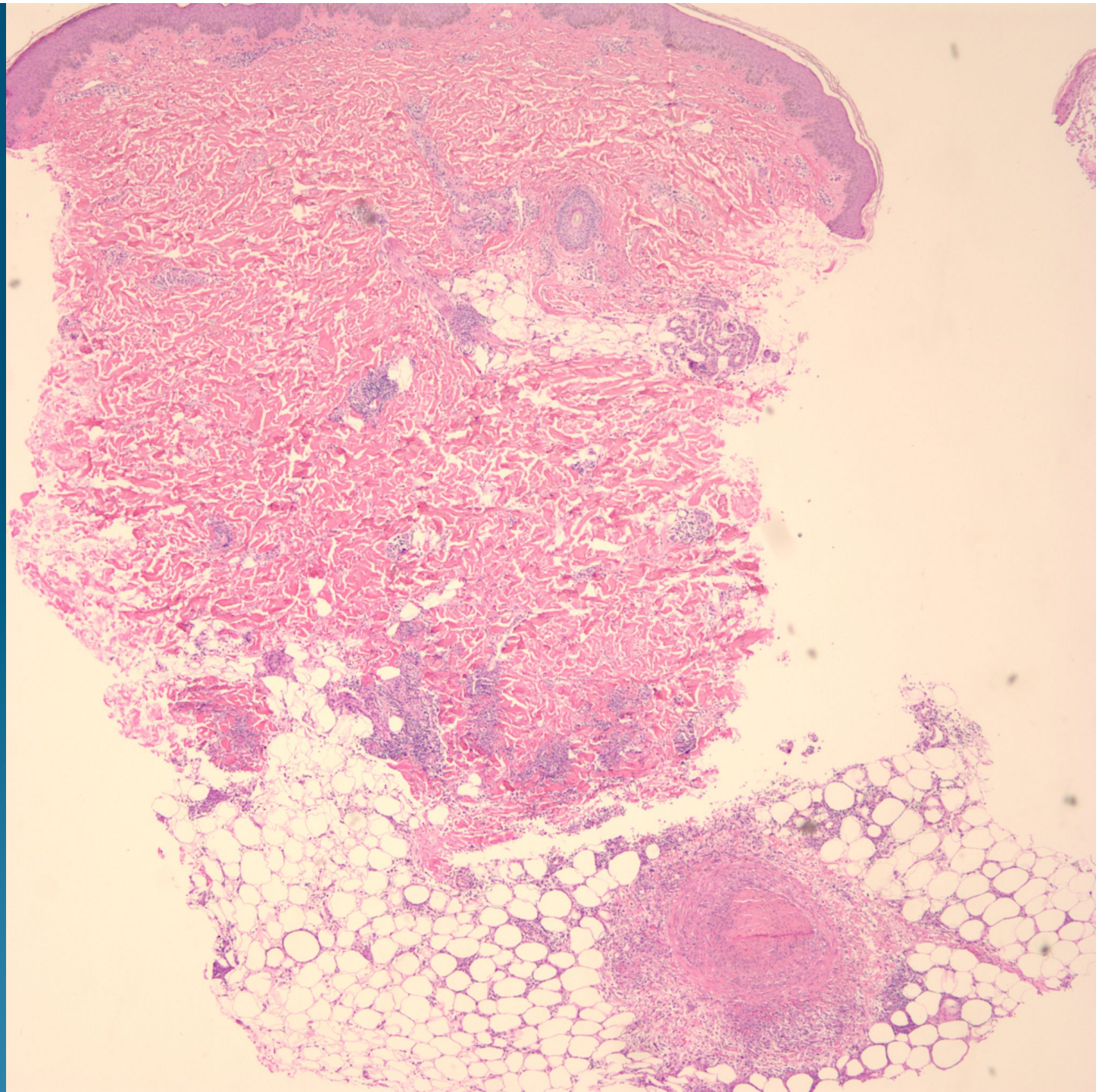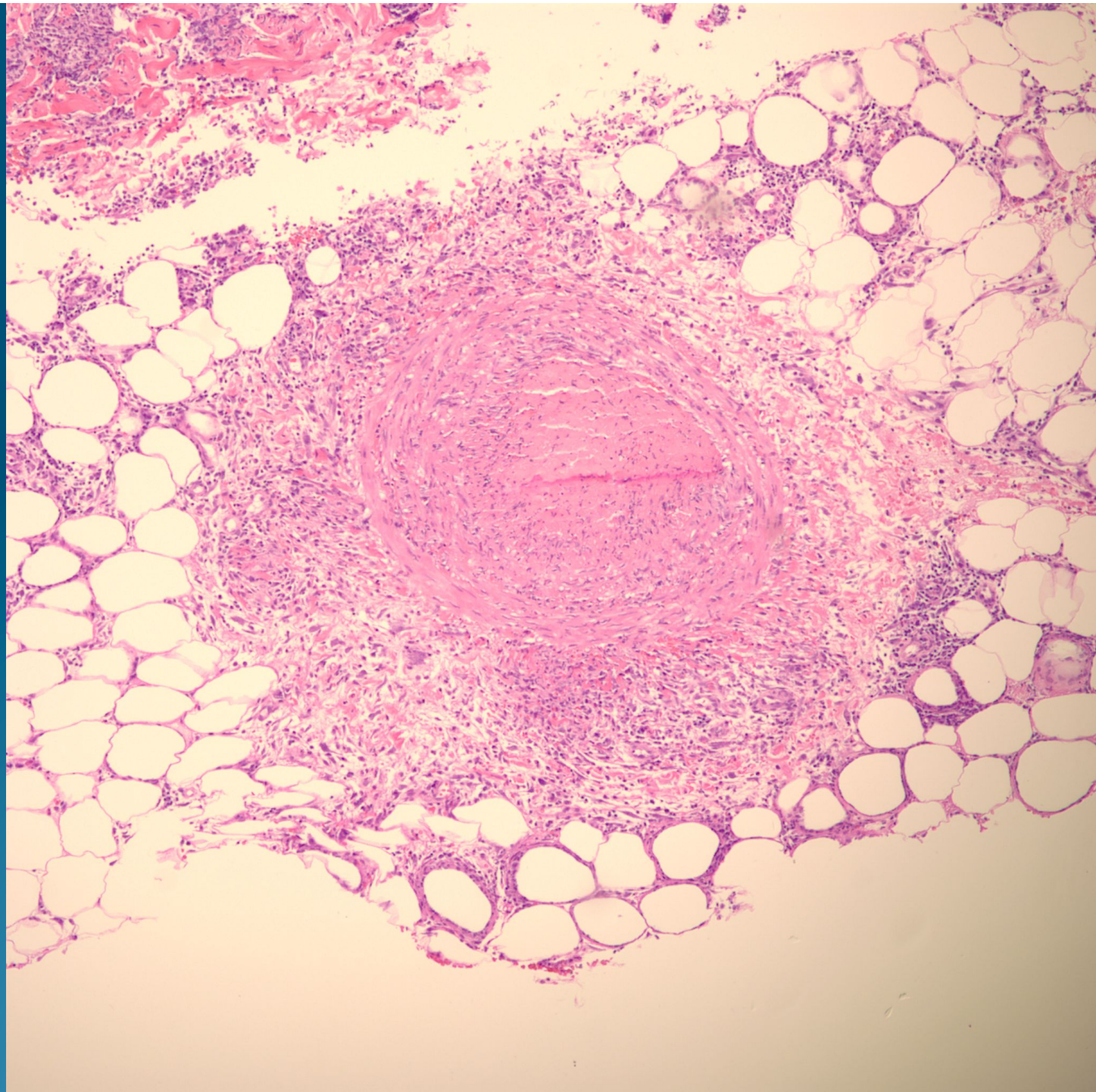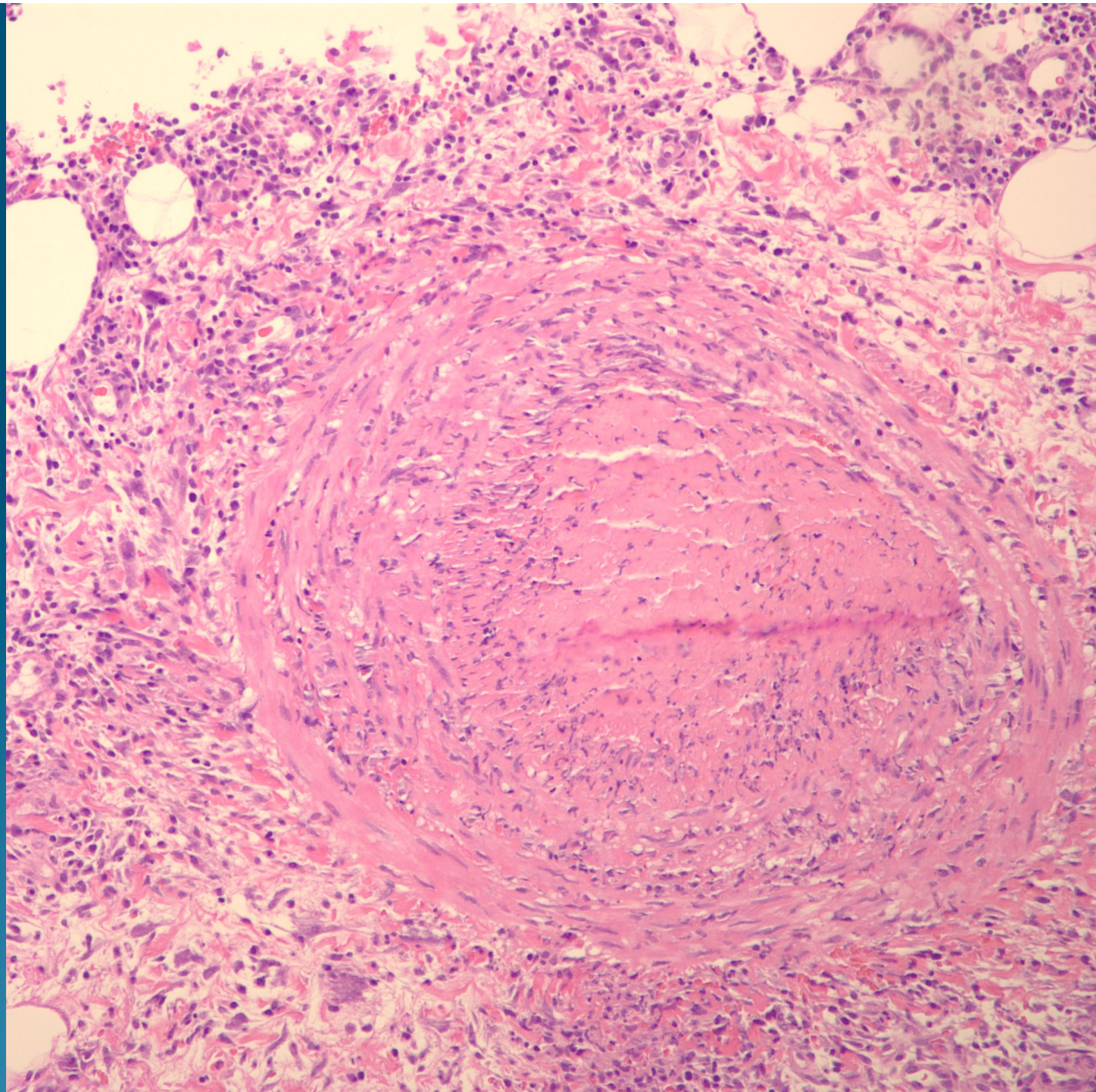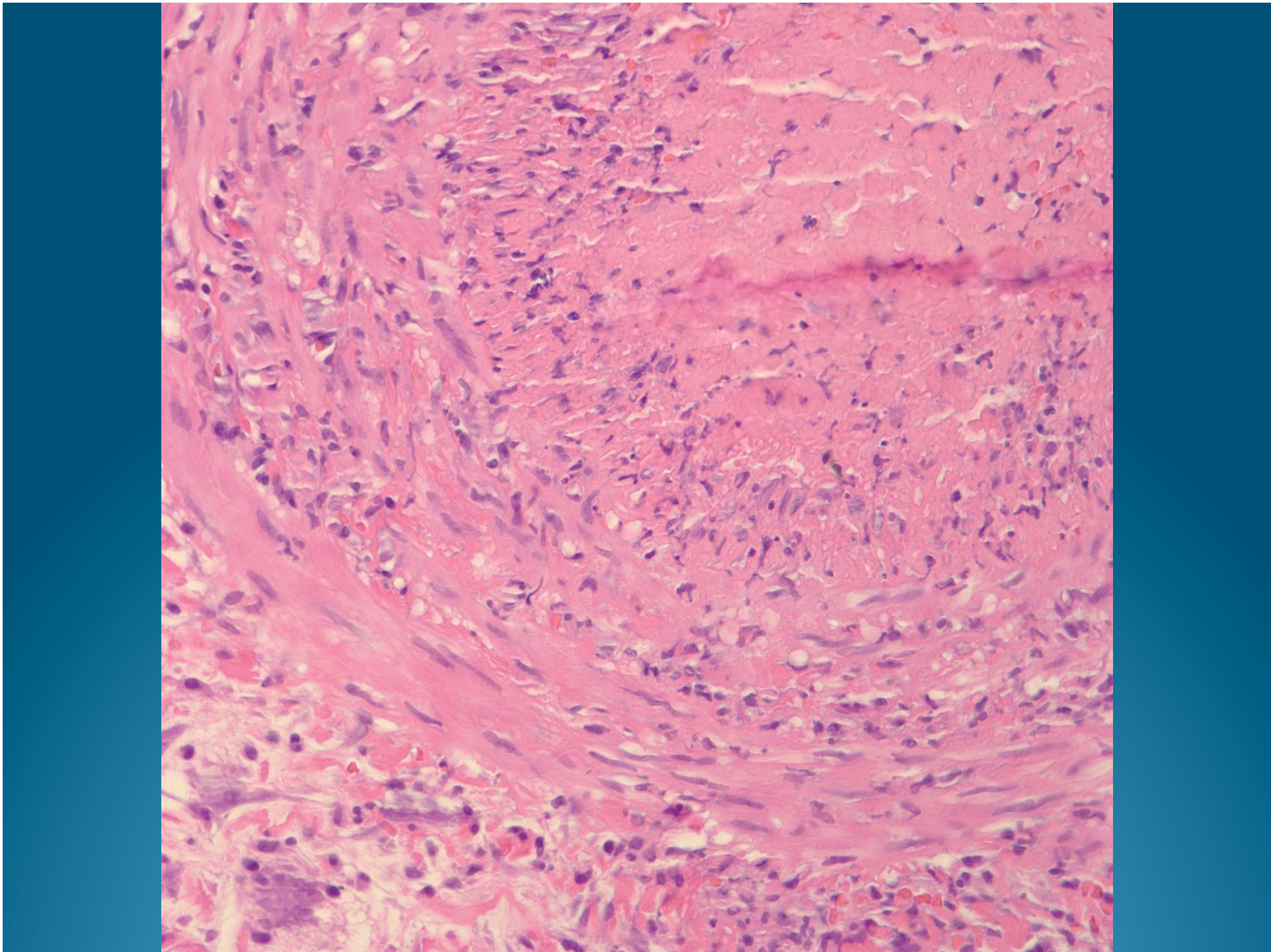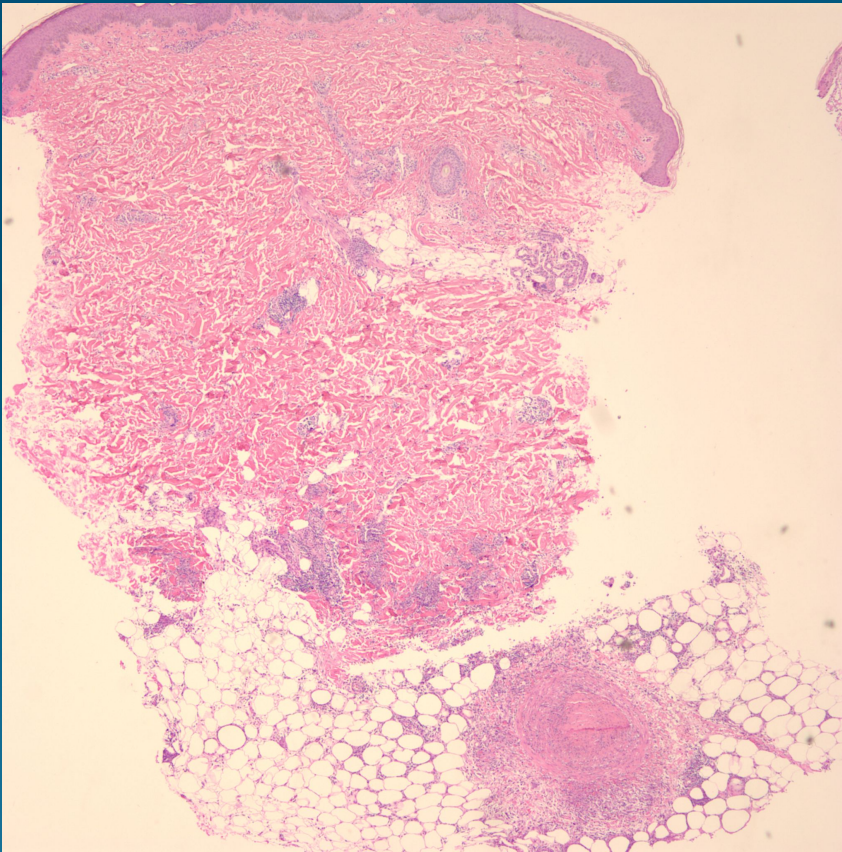


What is the best diagnosis?

- A. Erythema nodosum
- B. Lymphomatoid papulosis
- C. Lipomembranous panniculitis
- D. Behcet's syndrome
- E. Nodular vasculitis

Neutrophilic dermatosis and
vasculitis/panniculitis consistent
with Behcet's syndrome

Pearls



- Neutrophilic dermatosis with accompanying panniculitis and subcutaneous vasculitis
- Clinical-pathological correlation
- Rule out nodular vasculitis, polyarteritis nodosa, other neutrophilic dermatoses